

# The Child with a Limp

DR S Rajapaksa

[RCH CHld with a limp](#)

# Case:

- An 11 year old presents to ED with a 4 days history of a painful limp. He had been playing footie over the weekend and had fallen but then got up to play again.
- He has no history of recent infection or fever
- He weighs 70kg



What else would you  
want to know?

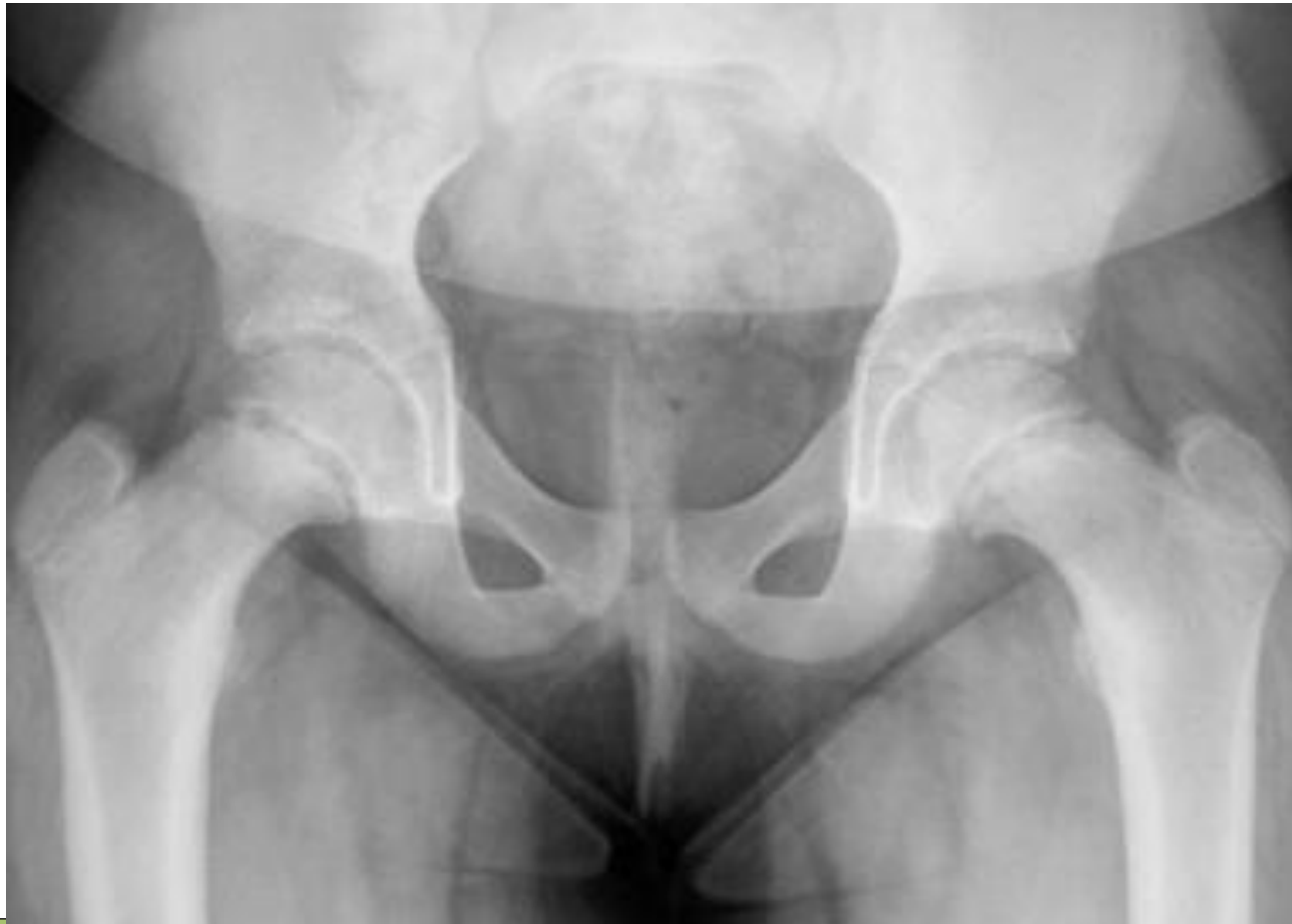# Case

- He has no past medical history; IUTD and no allergies
- He has pain in his left knee when walking
- On examination, the ED resident, Jane notes a limp but can find nothing else on examination to explain his predicament
- She orders a pelvic XR



Would you do anything differently?

What do you think?





What is your differential list?

# Case

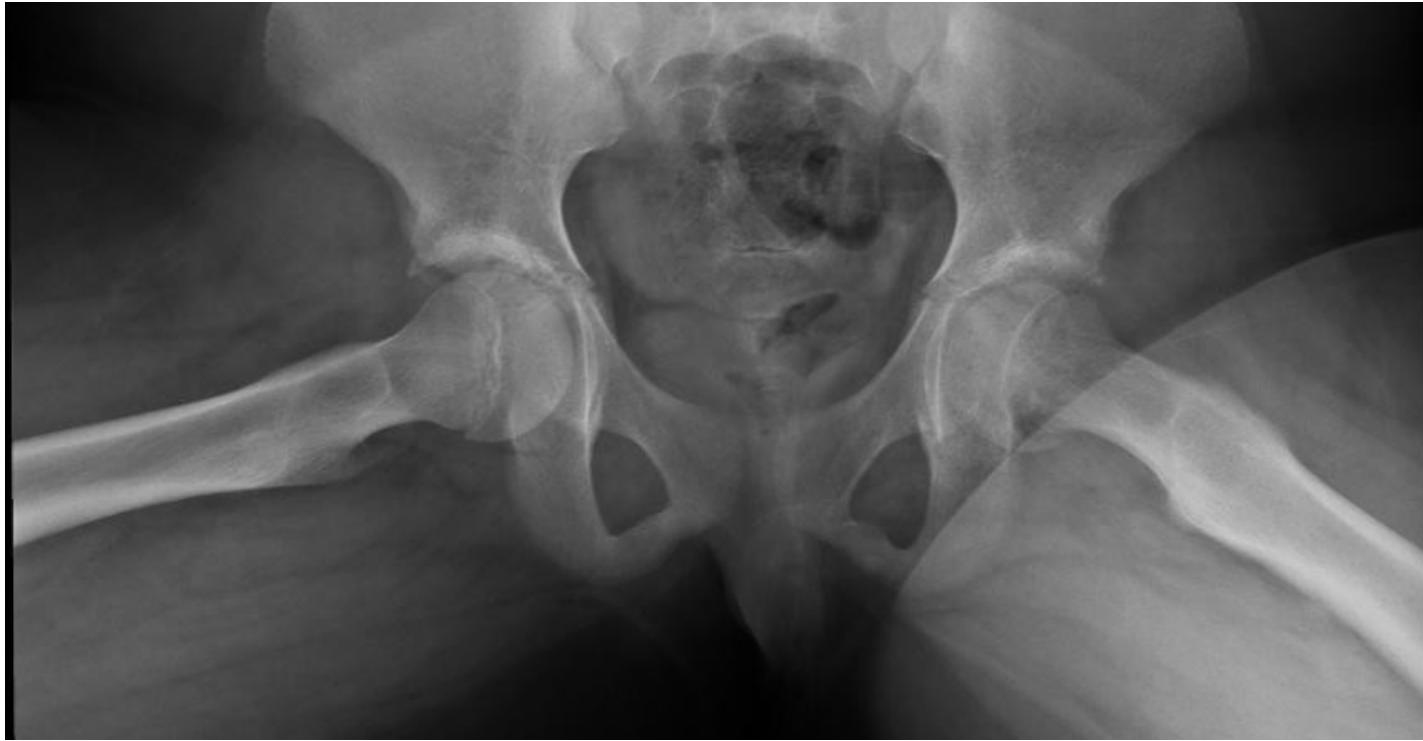- He is sent home with the diagnosis of a **thigh sprain**
- He is booked to paediatric clinic in view of his obesity
- The family do not attend the paed registrar clinic.
- He is seen in ED 4 weeks later with ongoing limp and can no longer weight bear on his left leg



# Case

- He is seen by the ED consultant who notices that he keeps his left leg in external rotation and has limited hip movement on that side
- He orders an AP and **frog lateral** hip XR

What is your diagnosis?



# Bilateral SUFE

SLIPPED UPPER FEMORAL EPIPHYSIS or SLIPPED  
CAPITAL FEMORAL EPIPHYSIS

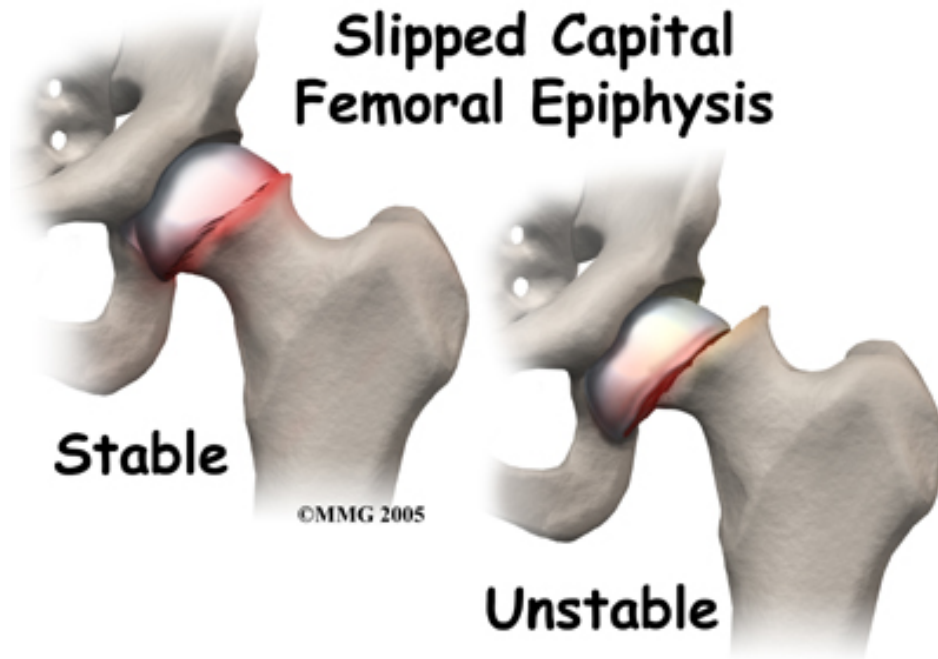
# Case

- He is referred to orthopaedics
- He requires surgery on both hips – more intensive than pinning the head of the femur in the joint as the SLIPs are extensive.
- How do you think this case could have been managed better?

# Improvements

- Better differential diagnosis
- Frog Lateral XR (as AP will miss early SUFE)
- Documented advice to return early if not improvement
- Review and discussion with a senior doctor prior to discharge – which must be documented

# What is SUFE?



# SUFE

## RCH SUFE CPG

- Usually occurs at the onset of puberty (12-15 years)
  - Esp tall and thin
  - short and obese
  - Afro-Caribbean
  - boys
  - family history.
- One quarter of cases are bilateral
- Hip, thigh and knee pain.
- Often initially a several week history of vague groin or thigh discomfort.
- May be able to weight bear, but is **painful**.
- Flexion of hip often also causes **external rotation**.
- May be **leg shortening**.

# Other differentials

- Perthe's - [RCH Perthe information](#)
- Trauma resulting in a fracture/ stress fracture
- Rheumatological disorder
- Muscle sprain
- Referred pain eg abdominal/ back/ genitalia



## Common diagnoses defined by age

Toddler (1-4 years)	Child (4-10 years)	Adolescent (>10 years)
<ul style="list-style-type: none"><li>• Developmental dysplasia of the hip (DDH)</li><li>• Toddlers fracture</li><li>• <u>Transient synovitis</u> of the hip (Irritable hip)</li><li>• Child abuse</li></ul>	<ul style="list-style-type: none"><li>• <u>Transient synovitis</u> of the hip</li><li>• <u>Perthes Disease</u></li></ul>	<ul style="list-style-type: none"><li>• Slipped upper femoral epiphysis ( <u>SUFE</u> )</li><li>• Overuse syndromes / stress fractures</li></ul>
<b>All ages:</b> <ul style="list-style-type: none"><li>• Infections: <u>Osteomyelitis / Septic Arthritis</u>, discitis, soft tissue, viral myositis</li><li>• Trauma (<b>see Fractures</b>)</li><li>• Non accidental or inflicted injury (see Child abuse guideline) - fracture, sprain, haematoma</li><li>• Malignancy - Acute lymphoblastic leukaemia, bone tumours, eg: spine or long bone</li><li>• Rheumatological disorders and reactive arthritis</li><li>• Intra-abdominal pathology, eg: appendicitis</li><li>• Inguinoscrotal disorders, eg: testicular torsion</li><li>• Vasculitis, serum sickness</li><li>• Functional limp</li></ul>		

## Case 2

- A 4 year old boy, Sam, presents to ED with a 3 day history of fever and a 24 hour history of limping and wanting to be carried. He screams if someone touches his leg. The whole family have been suffering from URTIs
- In ED, temp 37.6, sats 98%, HR 120 and RR 30

What is your differential?  
What would be your management?

## Case 2

- He is seen by the intern, Dan, who struggles to examine the child as he screams anytime the doctor or nurse approaches.
- There is no history of trauma
- He is developing normally
- IUTD and NKDA
- He has a younger 6 & 18 month old sisters at home and the mother is keen to get home asap to relieve the baby sitter.

# Examining the distressed child

- Analgesia

- Paracetamol
- Ibuprofen

- Distraction

- Bubbles
- Videos/ music
- Examine the parent/ favourite toy first
- Return when calmer
- Get help from another person – parent, doctor, nurse

## Case 2

- The intern speaks to the ED registrar who advises ibuprofen
- The intern is worried about septic arthritis

Do you agree with this diagnosis?

What is your management?

## Case 2

- The intern orders a AP hip XR – he looks at the film and believes it is normal.
- He attempts to take blood for CRP, FBE

Do you agree with this plan?

## Case 2

- He is unsuccessful with the bloods.
- After pain relief, Sam is alert and happily playing on his mother's smart phone.
- Sam's mother is keen to go home to see her younger daughters and is pestering Dr Dan to be discharged.
- Dr Dan now believes this is Transient Synovitis as the child looks so well and discharges Sam

Do you agree with this plan?

## Assessment

### Important features in the history include:

- Duration of symptoms
- Complete refusal to weight bear
- Trauma - there is often a coincidental history of trauma in a non-traumatic condition or there may be no history of trauma and the child may have a significant injury.
- Preceding illness - there is often a history of a simple viral infection preceding a transient synovitis or reactive arthritis
- Fever or systemic symptoms - suggests infective or inflammatory causes
- Pain - site and severity. Pain on changing the nappy, causing back flexion, may be present in discitis
- Morning stiffness
- Previous injuries or child protection concerns

### Examination:

- General appearance, temp
- Gait - running may exaggerate a limp
- Neurological examination - look for ataxia, weakness
- Generalised lymphadenopathy (viral infection / haematological cause)
- Excessive bruising or bruising in unusual places (NAI, haematological)
- Abdomen, scrotum and inguinal area (masses)
- Bony tenderness
- All joints
  - knee pain can be referred from the hip, and thigh pain can be referred from the spine
  - Include sacro-iliac joints and spine in joint assessment - look for pain on flexion and/or midline tenderness which may be present in discitis
  - Exaggerated lordosis (discitis)
  - Hip abduction and internal rotation are often the most restricted movements in hip pathology



## Investigations:

Unless suspecting a specific diagnosis, investigations are usually not required in children with limp <3 days duration.

Discuss with senior staff, then *consider*:

- Bloods:
  - FBE, CRP, ESR, blood culture
- Imaging:
  - plain films
  - Further imaging should be discussed with senior staff:

Imaging may demonstrate:

Plain x-rays	Ultrasound scan	Bone scan	CT / MRI
<ul style="list-style-type: none"><li>• Perthes / SUFE</li><li>• Chronic osteomyelitis (bony changes only evident after 14 - 21 days)</li><li>• Tumours</li><li>• Developmental dysplasia of hips (&gt; 6 months of age)</li></ul>	<ul style="list-style-type: none"><li>• septic hip</li></ul>	<ul style="list-style-type: none"><li>• Osteomyelitis</li><li>• Discitis</li><li>• Perthes</li><li>• Occult fracture</li></ul>	<ul style="list-style-type: none"><li>• Only after orthopaedic consultation</li></ul>

## Case 2

- 3 days later Sam and his mother return to ED. He has continued to spike fevers, presents with temp 40 and is lethargic. He is refusing to walk

What is your differential diagnosis?

## Case 2

- Sam receives pain relief (ibuprofen and paracetamol)
- He has no active or passive movement of the right leg
- He has no rashes
- He is mildly dehydrated
- Temp 40, RR 30, HR 136, sats 100%, BP s85

## Case 2- Management:

- Analgesia
- IV access – FBE (WCC 18), CRP (93), ESR (100), blood cultures, blood film (excludes ALL), UEC
- Hip XR (normal) and US
- Orthopaedic review
  - Diagnosis: **SEPTIC ARTHRITIS**
  - He is taken to theatre for a hip washout after the US shows significant effusion and ? Pus
  - His BC and joint fluid grow **staph aureus**



How do you think this case was managed?

What could have been done better?

# Improvements

- Missed key points in history and examination
- Would have benefitted from senior input (was not working within his competency)
- Didn't consider all differentials
- Inadequate investigations
- Falsely reassured by child being afebrile in ED and improvement following pain relief without completing examination
- Pressured by mother's desire for discharge and failed to complete full assessment
- Clear documented instructions for review if not improving

# Septic arthritis & osteomyelitis

## RCH Septic arthritis & osteo

### CPG

- Commonly hip, knee, ankle, shoulder, elbow.
- Most often children <2yrs.
- Early features often **non-specific**
- Child often very unwell.
- Pain often present at rest, **resistance to attempted movement of the hip.**
- Older children usually reluctant to weight bear, may be more aware of referred pain in the knee.
- **Hip is kept flexed, abducted and externally rotated.**

## Features

There is considerable overlap in the presentation of osteomyelitis and septic arthritis

Osteomyelitis	Septic arthritis
<ul style="list-style-type: none"><li>• Subacute onset of limp / non-weight bearing / refusal to use limb</li><li>• Localised pain and pain on movement</li><li>• Tenderness</li><li>• Soft tissue redness / swelling may not be present &amp; may appear late</li><li>• +/- Fever</li></ul>	<ul style="list-style-type: none"><li>• Acute onset of limp / non-weight bearing / refusal to use limb</li><li>• Pain on movement and at rest</li><li>• Limited range / loss of movement</li><li>• Soft tissue redness / swelling often present</li><li>• Fever</li></ul>

What are the likely organisms?



# Septic arthritis/ osteomyelitis

- Etiology
  - Staph aureus
  - Group A Strep
  - *Kingella kingae*
  - Neonates: E. coli, Candida, GBS
  - Adolescents: N. Gonorrhoea
  - Sickle cell - Salmonella
- Usually hematogenous seeding
  - Extension of osteomyelitis
  - Direct inoculation into joint from penetrating trauma

# Differentials

- Transient synovitis
- Trauma and fracture
- HSP
- Referred pain – abdomen; genitalia; neurological eg GBS

# Transient synovitis

## RCH Transient synovitis

- Non-infectious, inflammatory condition
- Usually children 3 – 8yrs
- May follow viral URI
- Mild fever, limp, fussiness
- ***Minimal limitation of range of motion passively***
- ESR, CRP, WBC usually normal
- Managed with rest, NSAIDs, close follow up

# RED FLAGS!

- Child <3y
- Unable to weight bear
- Fever
- Systemic illness
- >9y with pain or restricted hip movements

# Examining a child's gait - pGALS

- [pGALS - video of examining child's musculoskeletal system](#)
- [RCH PGALS pdf](#)

# Resources

- Check out the following resources for tips on history taking; differentials and investigation and management
- [RCH child with limp CPG](#)
- [RCH acutely swollen joint CPG](#)
- [RCH Paediatric fractures CPG](#)